D

Vaccinated COVID convalescents were found to have increased T-cell activation (a selective uptake of [18F]F-AraG) in many anatomical regions (thoracic spinal cord, cauda equina, lumbar and iliac crest, bone marrow, brainstem, aortic arch, pulonary artery, lower lung lobes, pharyngeal tonsils, hilar lymphoid tissue, proximal colon wall, rectal wall, and the right heart ventricle wall) and SARS-CoV-2 spike protein RNA in rectosigmoid cells up to 2.5 years after acute infection | 1

Infection with severe acute respiratory syndrome coronavirus type-2 (SARS-CoV-2) can lead to a new disease called long-COVID or post-acute COVID-19 syndrome (PACS). Long/post-COVID represents a heterogeneous nosological entity, despite similar or overlapping symptoms between patients. Numerous studies suggest that viral persistence, inflammation, and immune dysregulation could play a significant role in post-acute/long COVID syndrome, but its pathophysiology remains unclear. In this study, the researchers from the United States used whole-body positron emission tomography (PET) with a novel radiopharmaceutical [18F]F-AraG (fluorine-18-labeled-arabino-furanosyl-guanine) to localize activated T-cells in COVID convalescents with or without post-COVID symptoms. They also investigated the presence of SARS-CoV-2-specific RNA in rectosigmoid cells from participants diagnosed with post-COVID syndrome who underwent colorectal biopsy.

A novel radiopharmaceutical agent [18F]F-AraG is a highly selective and sensitive tracer that enables anatomical localization of activated CD8+ and CD4+ T lymphocytes. Previous i*n vivo* murine models have confirmed a selective uptake of [18F]F-AraG by activated T-cells.

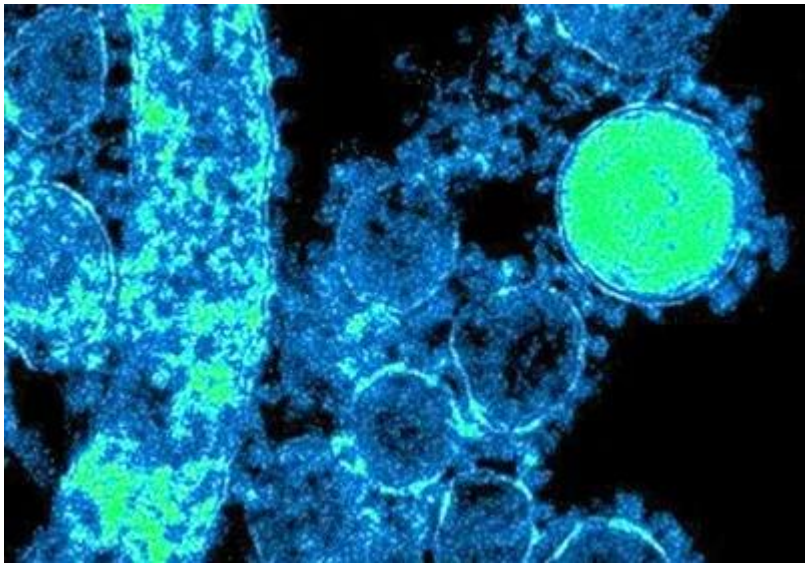

About the study

The study enrolled two groups of COVID convalescents and pre-pandemic controls. The first group of COVID convalescents were participants in the early post-acute phase of COVID-19 (less than 90 days after the onset of COVID-19 symptoms), and the second group were participants in the later post-acute phase (more than 90 days after the onset of COVID-19). Participants who underwent [18F]F-AraG PET before 2020 were pre-pandemic controls.

Most participants were infected with SARS-CoV-2 before the emergence of Omicron variants, and only two were hospitalized during the acute infection. One participant was infected during the ancestral wave but experienced two documented re-infections with presumed Omicron variants. Over the study period, no other participants had SARS-CoV-2 reinfection between the initial COVID-19 episode and PET imaging, and none of the subjects had subsequent positive COVID-19 PCR or antigen tests after the initial confirmatory test.

Vaccinated COVID convalescents were found to have increased T-cell activation (a selective uptake of [18F]F-AraG) in many anatomical regions (thoracic spinal cord, cauda equina, lumbar and iliac crest, bone marrow, brainstem, aortic arch, pulonary artery, lower lung lobes, pharyngeal tonsils, hilar lymphoid tissue, proximal colon wall, rectal wall, and the right heart ventricle wall) and SARS-CoV-2 spike protein RNA in rectosigmoid cells up to 2.5 years after acute infection

All participants, except one, had received at least one COVID-19 vaccine before the PET imaging. The study team was not informed that one participant received a booster vaccine dose six days before imaging.

During the first visit, participants completed a questionnaire that assessed demographics, medical history, the onset of COVID-19, treatment history, and vaccinations. The authors stated that they performed PET imaging more than 60 days after any vaccine dose to minimize the effect of vaccination on T-cell activation.

The presence of virus-specific RNA in rectosigmoid cells from participants diagnosed with post-COVID syndrome who underwent colorectal biopsies was assessed with a quantitative PCR assay and *in situ* hybridization.

Results

The study included 24 COVID convalescents and 6 pre-pandemic controls. COVID convalescents were divided into two groups: 9 in the early post-acute phase, and 15 in the later post-acute phase. In the first group, three participants completely recovered, and six did not. In the second group, three participants completely recovered, and 12 developed long COVID symptoms. The median age of the participants was 39.5 years (range 26 to 65), 11 were women, and 13 were men.

The median number of long COVID symptoms was 5.5 (ranging from 0 to 15). Fatigue (n=16) and neurocognitive complaints (n=14) were the most frequent symptoms.

PET results

The [18F]F-AraG was given intravenously. COVID convalescents, including those with and without long COVID symptoms, had higher [18F]F-AraG uptake, showing elevated T-cell activation, in many anatomical regions than pre-pandemic controls. COVID convalescents had higher [18F]F-AraG uptake in the thoracic spinal cord, cauda equina, lumbar and iliac crest, bone marrow, brainstem (pons), aortic arch, pulmonary artery, lower lung lobes, pharyngeal tonsils, hilar lymphoid tissue, proximal colon wall, rectal wall, and the right heart ventricle wall compared to the pre-pandemic controls. Elevated T-cell activation was observed in numerous individuals who did not develop long COVID symptoms.

Higher [18F]F-AraG uptake in certain tissues, such as the spinal cord, hilar lymph nodes, and colon/rectal wall, was associated with post-COVID symptoms. Participants with pulmonary symptoms of long COVID, such as cough, shortness of breath, or dyspnea, had higher uptake of [18F]F-AraG in their lower lung and hilar regions of interest than participants without these symptoms. Interestingly, men had a higher uptake of [18F]F-AraG in hilar regions of interest than women.

The participants who reported more than five symptoms of long COVID at the time of PET/CT imaging had higher levels of circulating inflammatory markers and proteins involved in immune responses, chemokine signaling, inflammatory responses, and nervous system development. Participants with higher [18F]F-AraG uptake in the lower lung had upregulated clusters of gene products involved in the inflammatory response, fibroblast transformation, and response to mitogenic stimulation.

Vaccinated COVID convalescents were found to have increased T-cell activation (a selective uptake of [18F]F-AraG) in many anatomical regions (thoracic spinal cord, cauda equina, lumbar and iliac crest, bone marrow, brainstem, aortic arch, pulonary artery, lower lung lobes, pharyngeal tonsils, hilar lymphoid tissue, proximal colon wall, rectal wall, and the right heart ventricle wall) and SARS-CoV-2 spike protein RNA in rectosigmoid cells up to 2.5 years after acute infection

The correlation analysis between the biodistribution of [18F]F-AraG and the timing of immunization revealed that the time from the most recent vaccination to PET imaging had minimal impact on the [18F]F-AraG uptake in most tissues. The only exception was a higher uptake in the lower gut wall detected in individuals who received the last COVID-19 vaccine less than 180 days before the PET imaging.

Chest computerized tomography (CT) scan demonstrated mild apical scarring and/or reticulation in four participants, indicating mild pulmonary fibrosis. Other participants had normal CT scans, except for incidental findings not attributable to prior COVID-19 infection (*e.g.* calcified granulomas).

Rectosigmoid tissue analysis

As the abovementioned findings revealed that many COVID convalescents had higher uptake of [18F]F-AraG in the proximal colon and rectal wall than pre-pandemic controls, the authors hypothesized that viral persistence in the gastrointestinal tissues may be responsible, at least in part, for the migration of activated T-cells. Therefore, they assessed the persistence of the virus in rectosigmoid tissue collected by flexible sigmoidoscopy in five participants who underwent PET imaging 158 to 676 days after initial SARS-CoV-2 infection.

At the time of the biopsy, all five participants reported at least one symptom of long COVID. None of them had received the COVID-19 vaccine in the prior month. Three of five COVID convalescents did not have detectable IgG specific for SARS-CoV-2 nucleocapsid protein in a short time from tissue collection.

SARS-CoV-2 spike (S) protein RNA was detected in rectosigmoid cells in all participants who underwent biopsy. Almost all S protein RNA was found in cells located in the *lamina propria*, without any epithelial signal. A small number of spike protein RNA+ cells expressed CD68, a macrophage monocyte lineage marker.

Conclusion

This whole-body PET study with a novel radiopharmaceutical agent showed that COVID convalescents had higher uptake of [18F]F-AraG in numerous anatomical regions than pre-pandemic controls up to 2.5 years after initial infection. As [18F]F-AraG enables anatomical localization of activated T-cells, these results provide additional evidence for the role of tissue-based immune activation in the post-acute sequelae of SARS-CoV-2 infection. Additionally, SARS-CoV-2 spike protein RNA was detected in the rectosigmoid *lamina propria* of all five COVID convalescents who underwent colorectal biopsy, suggesting that viral persistence in the gastrointestinal tissues may be responsible, at least in part, for the migration of activated T-cells.

This study was published in Science Translational Medicine.

Journal Reference

Peluso MJ et al. Tissue-based T cell activation and viral RNA persist for up to 2 years after SARS-CoV-2 infection. SCIENCE TRANSLATIONAL MEDICINE 3 Jul 2024 Vol 16, Issue 754.

Vaccinated COVID convalescents were found to have increased T-cell activation (a selective uptake of [18F]F-AraG) in many anatomical regions (thoracic spinal cord, cauda equina, lumbar and iliac crest, bone marrow, brainstem, aortic arch, pulonary artery, lower lung lobes, pharyngeal tonsils, hilar lymphoid tissue, proximal colon wall, rectal wall, and the right heart ventricle wall) and SARS-CoV-2 spike protein RNA in rectosigmoid cells up to 2-5 years after acute infection

https://www.science.org/doi/10.1126/scitranslmed.adk3295

Peluso MJ et al. Multimodal Molecular Imaging Reveals Tissue-Based T Cell Activation and Viral RNA Persistence for Up to 2 Years Following COVID-19. MedRxiv preprint. https://www.medrxiv.org/content/10.1101/2023.07.27.23293177v1.full