The infection with severe acute respiratory syndrome coronavirus type-2 (SARS-CoV-2) can lead to a new disease called long COVID or post-acute COVID-19 syndrome (PACS). Long COVID syndrome is more common in hospitalized survivors, but, even those who have experienced mild acute COVID-19 can develop a wide range of frequent, persistent, and disabling symptoms. The most frequent symptoms of long COVID syndrome include fatigue, muscle weakness, dyspnea, cough, headache, cardiac arrhythmias, cognitive deficits, anxiety, depression, and thromboinflammatory events, such as ischemic stroke, pulmonary embolism, and deep vein thrombosis. The mechanisms underlying long COVID and the differences in its manifestation are poorly understood. In this study, the author from the United States presented four patients who suffered from different symptoms of long COVID syndrome and who were treated with acyclovir, a nucleoside analog that selectively inhibits the replication of herpes simplex virus type 1 and 2 and varicella-zoster virus. The results showed that administration of acyclovir clinically resolved or significantly improved long COVID symptoms in all patients. Since the symptoms returned after discontinuation of treatment, chronic use of acyclovir for weeks to months was required in all cases to achieve sustained therapeutic benefit.

It should be noted that another study also presented four patients diagnosed with long COVID who were successfully treated with acyclovir. Acyclovir, which was approved for medical use in 1981, significantly improved long COVID symptoms, especially those associated with encephalopathy and neurological sequelae. (German ER, et al. Treatment of Long-Haul COVID Patients With Off-Label Acyclovir. Cureus 15(4): e37926). https://www.cureus.com/articles/128535-treatment-of-long-haul-covid-patients-with-off-label-acyclovir#!/

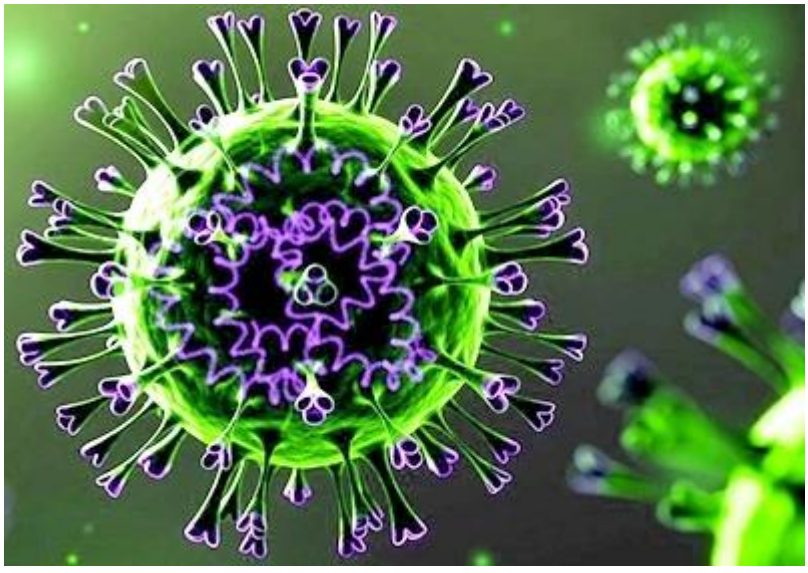

*About the study*

In all presented cases, a reverse transcription polymerase chain reaction (rt-PCR) of nasopharyngeal swabs for SARS-CoV-2 confirmed a diagnosis of COVID-19. After the acute infection ended, all patients tested negative for SARS-CoV-2.

***Case One***

A 16-year-old male presented with a history of migraines, which began when he was ten years old. At the age of 15, he had a brain concussion, and the frequency of headaches increased, occurring two to three times per week. The headaches became more severe, with nausea, increased light sensitivity, and a change in sleep pattern.

Four months after having a brain concussion, he got COVID-19. After COVID-19, the severity and frequency of migraines increased, and headaches occurred almost every day. He suffered from daily nausea, vomiting, and sensitivity to light and sound, and was unable to perform daily activities or attend school. He was treated with cetirizine, diphenhydramine, prochlorperazine, amitriptyline, ondansetron, meloxicam, botulinum toxin injections, and acupuncture, but headaches persisted for ten months with minimal improvement.

At that time, the patient started treatment with acyclovir at a dose of 800 mg four times a day. The symptoms such as the severity and frequency of headaches, sensitivity to light and sound, nausea, and vomiting were improved or greatly diminished after a 5-day course. He became fully functional and was able to go back to school. However, after the completion of acyclovir treatment, the symptoms started to return, and the 5-day course was repeated six times. Each time there was a marked improvement, but, when the acyclovir was discontinued, the symptoms returned. The patient is now taking acyclovir continuously.

**Case Two**

A woman aged 57 years underwent a craniotomy and microvascular decompression procedure for trigeminal neuralgia 15 years before the COVID-19 infection. After the procedure, she recovered with a complete resolution of pain. Two weeks after recovery from COVID-19, she again experienced trigeminal neuralgia and facial pain that was as severe as the pain she had experienced fifteen years ago.

She started treatment with acyclovir at a dose of 800 mg four times daily. The facial pain subsided within 24 hours and disappeared after 48 hours. After completing three 5-day courses of acyclovir, the facial pain returned. Treatment with acyclovir was continued for four months, and then gradually reduced over ten days. The patient has been pain-free for nine months.

***Case Three***

A 63-year-old woman, who was very active and walked three kilometers a day before COVID-19, experienced respiratory symptoms during the acute phase of COVID-19. After the COVID-19, she couldn’t walk without dyspnea and tiredness. She used oxygen nasal prongs at night, and her PO2 was in the 80s mm Hg. These symptoms of long COVID-19 continued for 18 months.

She started treatment with acyclovir at a dose of 800 mg four times daily for 5 days and experienced some improvement. After the next two 5-day courses of acyclovir, the treatment was continued for four months. She experienced improvement, and could again walk three kilometers per day. Her PO2 increased to 90 mm Hg. Treatment with acyclovir was

gradually reduced over one week, and finally discontinued, but her long COVID symptoms returned, so, treatment with acyclovir was started again.

### *Case Four*

A 40-year-old woman had COVID-19 six months after a lumbar microdiscectomy for radicular leg pain. Three to four weeks after the COVID-19, the radicular pain returned. The magnetic resonance imaging of the lumbar spine revealed a negative result for disc recurrences. She began the treatment with acyclovir at a dose of 800 mg four times daily, and her leg pain was gone within three days. Treatment was continued for three weeks, and then, gradually reduced. The radicular pain did not return.

*Conclusion*

These four case reports have shown that acyclovir clinically resolved or significantly improved long COVID symptoms in all cases. The author, however, emphasized that despite its initial effect, chronic use of acyclovir over weeks to months was required in all cases to achieve sustained therapeutic benefit. Adverse effects were not observed with chronic therapy. The researcher concluded that further studies should verify these findings.

This article was published in the American Journal of Infectious Diseases.

### *Journal Reference*

Beatty RM. Long COVID-19 Symptoms Remedied by Anti-Viral Treatment in Neurosurgical Patients. American Journal of Infectious Diseases. Volume 19 No. 3, 2023, 39-44. (Open Access) https://doi.org/10.3844/ajidsp.2023.39.44