The transfemoral approach is typically used for coronary angiography, the gold standard procedure for evaluating atherosclerotic coronary artery disease. The transradial route, however, has recently emerged as the favored path. After the left internal mammary artery, the radial artery is the second most popular artery graft of choice. Therefore, short-term and long-term consequences of radial artery thrombosis are considered very significant. In this study, the authors from Turkey investigated the occurrence of radial artery thrombosis after the transradial route of coronary angiography and related risk factors for its occurrence.

The researchers pointed out that radial artery thrombosis is the most prevalent complication of transradial interventions, but data are limited due to the asymptomatic course of this complication. Previous studies reported that repetitive puncture, increased compression time, and high compression pressure increase the frequency of radial artery thrombosis, while heparin usage decreases it.

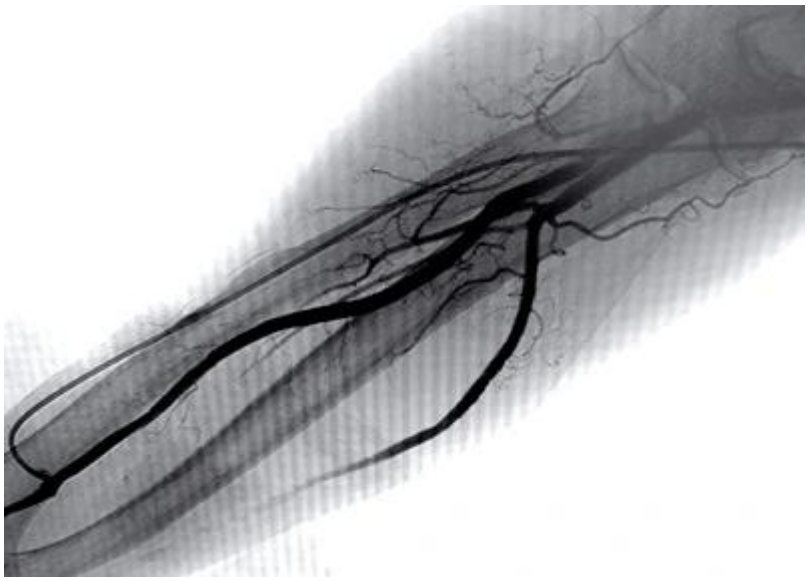

About the study

This prospective study included patients aged 18 years or older who either presented with acute coronary syndrome or required coronary angiography for diagnostic evaluation. All procedures were conducted *via* the right proximal radial artery route. Patients were excluded from the study if they had known contraindications to radial access, including abnormal Allen's test results, known radial artery occlusion from previous procedures, or the arterio-venous fistulas in the arm. The authors recorded the following data: patient's height, weight, body mass index (BMI), laboratory analyses (complete blood count, renal function tests, blood glucose level, thyroid function tests, lipid profile), cardiac risk factors, medications used before the procedure, heparin dose administered during the procedure,

and duration of radial band.

Radial current velocities were recorded in the proximal and distal areas of the radial artery. Radial artery thrombosis was assessed using color Doppler ultrasound immediately after radial band removal.

Results

A total of 150 consecutive patients were included, 59 were men and 41% were women. The mean age was 59.5 ± 11 years. Most patients (87%) presented with suspicion or evidence of ischemia, while 13% presented with acute coronary syndrome.

The mean BMI was 28.9 ± 5.2 kg/m^2. Comorbidities included hypertension (63%), diabetes mellitus (33%), hyperlipidemia (24%), history of coronary artery disease (26%), chronic kidney disease (13%), cerebrovascular disease (5%), and heart failure (7%). Most patients (81%) were under anti-thrombocyte treatment.

13% (20 patients) developed radial artery thrombosis. This rate is consistent with the previous studies' rates, which were between 10% and 15%. 3% of patients had partial occlusion and 11% had complete occlusion.

Radial artery thrombosis was more common in women than men (19.6 *vs*. 8.9%).

The patients diagnosed with radial artery thrombosis formed the study group, while those without this diagnosis were referred to as the control group. There was no significant difference between the groups concerning age, hypertension, diabetes mellitus, hyperlipidemia, smoking, chronic renal diseases, cerebrovascular diseases, BMI, or laboratory parameters, except for the neutrophil counts. The groups differed significantly in proximal and distal flow rates and compression time.

The univariate analysis identified several factors as potential predictors of radial artery thrombosis, such as female gender, hypertension, history of coronary artery disease, anti-thrombocyte drug usage, compression time, indication for coronary angiography, hematocrit levels, neutrophil count, creatinine levels and estimated glomerular filtration rate (e-GFR). However, only hypertension showed a significant association.

The multivariable regression analysis identified hypertension, anti-thrombocyte treatment, compression time, hematocrit levels, and creatinine levels as independent predictors of radial artery thrombosis. Although radial artery thrombosis was more common in women than in men, female gender did not prove to be an independent predictor in the multivariate analysis.

Conclusion

This study reported an incidence of 13% of radial artery thrombosis after proximal transradial coronary procedure, confirming that radial artery thrombosis remains a significant complication. Since a conventional pulse examination may not adequately detect

radial artery thrombosis, the authors suggested that color Doppler ultrasound should be considered for radial artery patency assessment after the procedure in high-risk individuals. Alternatively, ultrasound-guided access could reduce the risk of thrombosis by minimizing vascular trauma during cannulation. They also noted that further research should establish standardized protocols for the prevention and early detection of radial artery thrombosis and explore the potential benefits of newer techniques in reducing this complication.

This article was published in Heart International.

Journal Reference

Koc AY, E, Naldemir IF, Ozde C. Radial artery thrombosis and Associated Risk Factors in Patients Undergoing Radial Coronary Angiography. Heart International. 2024; 18 (2): 37–43. (Open Access) https://doi.org/10.17925/HI.2024.18.2.1